

PATIENT

Skye Graham

SPECIES

Canine

BREED

Great Pyr Mix

SEX

FS

AGE

10 year

WEIGHT

92

PRESENTING CLINICAL SIGNS

History: Recheck holter
Current medications: Sotalol 100mg
Pertinent prior holter results (6/22 MML): 190 VPCs, singles and one couplet

HOLTER MONITOR FINDINGS AND RHYTHM ASSESSMENT

Time analyzed	23:38h
Mean heart rate	76bpm
Maximum heart rate	229bpm
Minimum heart rate	52bpm
VPCs	20,855 singles
APCs	0

Interpretation: Dramatic increase in VPC frequency, although only singles are seen. Frequent bigeminy. No additional changes are seen.

Rhythm diagnosis: Sinus rhythm with frequent isolated VPCs.

RECOMMENDATIONS

The primary difference between this tracing and the 6/22 recording is a dramatic increase in VPC frequency (from <200 to over 20k). The markers of malignancy remain low, and no couplets, triplets or runs are appreciated.

It is unclear why high dose Sotalol was initiated in this case (presumably; kg v lbs are not specified), as the prior report did not recommend this medication based upon the results. It is assumed that the dramatic increase in frequency is secondary to the medication (an issue with anti-arrhythmics being possible pro-arrhythmic side effects), although a true increase in arrhythmic activity cannot be ruled out. Certainly discontinuing the medication is recommended, with reassessment of a holter ideally in another month. If this is not possible, as long as the patient is asymptomatic I would recheck the holter as able in this case, at a minimum within 6 months.

Monitor at home for any signs of persistent arrhythmias, such as lethargy or collapse.

Recheck echocardiogram as dictated by the ECG report.

INTERPRETED BY

Maggie Machen Lamy,
DVM, DACVIM
(Cardiology)

IMAGING PERFORMED BY

HOSPITAL NAME

Rockaway AH

REFERRING VET

Dr. Maniar

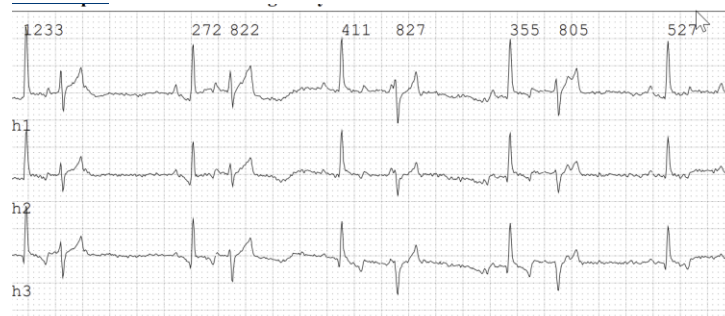
INVOICE

25407

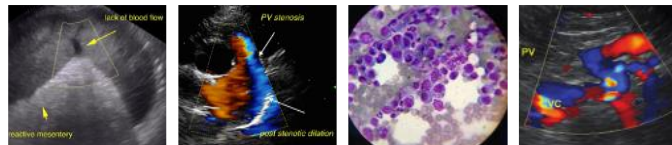
DATE

7/15/22

IMAGES



Bigeminy



PATIENT

Skye Graham

The information and recommendations provided are based on the images presented by the referring veterinarian. No evaluation can be communicated regarding pathology that was not visible in the image/video clips provided.

SPECIES

Canine

Thank you for this referral. If the clinical or image interpretation does not parallel your findings or if I can be of any further assistance please contact me.

BREED

Great Pyr Mix

Maggie Machen Lamy, DVM

Diplomate of the American College of Veterinary Internal Medicine (Cardiology)

info@sonopath.com

SEX

FS

AGE

10 year

WEIGHT

92

INTERPRETED BY

Maggie Machen Lamy,
DVM, DACVIM
(Cardiology)

**IMAGING
PERFORMED BY**

HOSPITAL NAME

Rockaway AH

REFERRING VET

Dr. Maniar

INVOICE

25407

DATE

7/15/22